

DEPARTMENT OF NUCLEAR MEDICINE AND MOLECULAR IMAGING

PET-CT SCAN REPORT

Patient Name	JEAN PIERRE BOODOO	Age	74Yr
Reg. No.	ACH-PET-00378	Sex	Male
Ref. By		Date	25 Mar 2026

Clinical Indication: HPE: metastatic carcinoma of poorly differentiated adenocarcinoma. PET CT was done for further evaluation.

Technique: Whole body images (vertex to mid-thigh) were acquired in 3-D mode 60 min after i.v. injection 5.6 mCi of 18F-FDG using a dedicated BGO PET-CT scanner. FBS before injecting 18F-FDG was 9.1 mmol/ L. IV contrast was given. Reconstruction of the acquired data was performed so as to obtain fused PET-CT images in transaxial, coronal and sagittal views.

FINDINGS:

BRAIN

FDG avid enhancing nodular lesion noted in parasagittal region in frontal lobe of brain (size ~2.5 x 2.5 cm, SUVmax 11.7) with perilesional edema.

Non FDG avid hypodense areas/ gliotic changes noted in left parietal region of brain-likely sequelae of chronic infarct.

Physiological FDG uptake is seen in rest of the brain.

(Note: All the brain lesions may not be apparent on FDG PET CT brain due to high background physiological FDG uptake in brain parenchyma. Suggested MRI correlation if clinically indicated)

HEAD AND NECK

No discrete enhancing mass lesion/focal abnormal FDG uptake is seen in nasopharynx/ oropharynx/ hypopharynx.

FDG avid Bilateral level IB, II, III, bilateral supraclavicular and level V cervical lymph nodes (largest in left supraclavicular region measuring ~4.9 x 5.3 cm, SUVmax 7).

Both lobes of thyroid gland appear normal in size. No evidence of hypodense lesions or focal abnormal FDG uptake.

Non FDG avid filling defect noted in left IJV- suggestive of thrombus.

\CHEST

Moderate right pleural effusion is seen. There is complete collapse consolidation involving right upper lobe with FDG uptake in medial portion (SUVmax 6.7). There is cut off of right upper lobar bronchus.

Emphysematous changes noted in both lungs.

Mild septal thickening with ground glass density changes noted in lingula and superior segment of left lower lobe.

Subsegmental atelectasis noted in right lower lobe.

Multiple FDG avid discrete and conglomerated thoracic lymph nodes are seen in prevascular, paraaortic, subaortic, bilateral upper and lower paratracheal, subcarinal, paraesophageal, internal mammary and bilateral hilar lymph nodes (largest conglomerated lymph nodal mass in bilateral lower paratracheal region measuring ~3.4 x 7.5 cm, SUVmax 5.5).

FDG avid bilateral anterior superior diaphragmatic lymph nodes are seen (largest on the left side measuring ~4 x 1.4 cm, SUVmax 5.6).

FDG avid bilateral axillary lymph nodes are seen (largest on the right side measuring ~2.9 x 1.4 cm, SUVmax 3.2).

Esophagus appears normal in morphology with no focal mural thickening or mass lesion or focal abnormal FDG uptake.

ABDOMEN AND PELVIS

Stomach appears normal in morphology with no focal mural thickening or mass lesion or focal abnormal FDG uptake.

Liver appears enlarged (size 21.7 cm). No evidence of hypoattenuating lesions or focal abnormal FDG uptake in the liver. No evidence of IHBRD. Gall bladder appears unremarkable with no evidence of calculi.

Spleen appears enlarged (size ~17 cm). Diffusely increased FDG uptake is seen in spleen (SUVmax 7.3).

Pancreas appears normal in size, morphology with no mass lesion/focal abnormal FDG uptake. No dilatation seen in the main pancreatic duct.

Small and large intestine appear unremarkable with no abnormal wall thickening or mass lesion or focal FDG uptake.

Bilateral adrenal glands appear normal in size with no focal nodularity or focal abnormal FDG uptake.

Both kidneys appear normal in size, shape and position. No abnormal mass lesion or focal abnormal FDG uptake seen. No evidence of renal calculi.

FDG avid abdominal, pelvic and retroperitoneal lymph nodes:

Gastrohepatic ligament, peripancreatic, periportal and portocaval lymph nodes (largest lymph nodal mass measuring ~6.8 x 12 cm, SUVmax 8, it is encasing celiac vessels and its branches). Pancreas appears to be

displaced anteriorly.

Discrete and conglomerated retroperitoneal lymph nodes in paraaortic, aortocaval and retrocaval regions (largest conglomerated lymph nodal mass measuring ~5.4 x 9.2 cm, SUVmax 7.2)

Mesenteric lymph nodes (largest measuring ~3.2 x 4.1 cm, SUVmax 6.9)

Bilateral common and external iliac lymph nodes (largest in left external iliac region measuring ~3.1 x 2.5 cm, SUVmax 4.4)

Trace free fluid noted in pelvis.

Prostate appears unremarkable.

FDG avid bilateral inguinal lymph nodes are seen (most FDG avid lymph node on right side measuring ~1 x 1.3 cm, SUVmax 4.1).

SKELETAL SYSTEM

FDG avid lytic lesion noted in T4 vertebral body (SUVmax 6.6).

Degenerative changes noted in the spine. **Diffuse heterogeneous FDG uptake is seen in marrow of multiple bones of axial and appendicular skeleton**. Rest of the visualized bones otherwise appear normal with no lytic or sclerotic lesion or focal abnormal FDG uptake.

Physiological tracer distribution is seen in the brain, myocardium and urinary bladder.

IMPRESSION:

HPE: metastatic carcinoma of poorly differentiated adenocarcinoma:


- Moderate right pleural effusion.
- Complete collapse consolidation involving right lung upper lobe with FDG uptake in medial portion.
- Multiple FDG avid cervical, thoracic, axillary, abdominal, pelvic, retroperitoneal and inguinal lymph nodes.
- Hepatosplenomegaly. Diffusely increased FDG uptake in spleen.
- FDG avid lytic lesion in T4 vertebral body.
- Diffuse heterogeneous FDG uptake is seen in marrow of multiple bones of axial and appendicular skeleton.
- FDG avid enhancing nodular lesion in parasagittal region in frontal lobe of brain with perilesional edema.
- With above scan findings to consider lymphoma. Suggested IHC correlation.



Dr Varsha Niranjana
*MBBS, Diplomate of National
Board(DNB)
Reg No.114710
Consultant Nuclear Medicine Physician*



Dr. Kishan Bhagwat
*MBBS, MD, DNB, EDiR
Reg.No.: 67636
Consultant Radiologist*

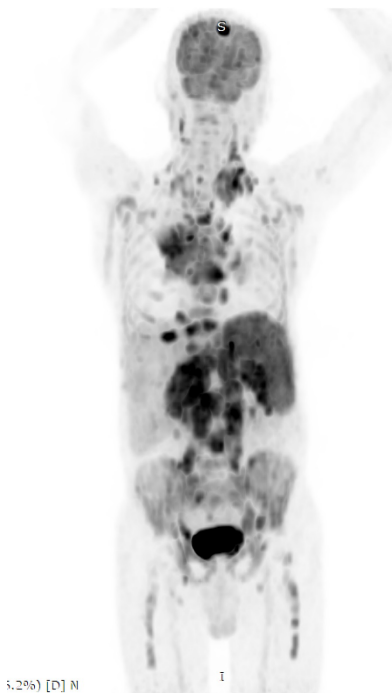


Dr. Krishnarjun P
*MBBS, MD
Reg.No.: KMC 97507
Consultant Radiologist*



Dr A. Shantaram Naojee
*MBBS , MD , Fellow Nuclear medicine
Reg.No. 00974
Consultant Nuclear Medicine Physician*

Note: This is an interpretation of radiological imaging which have to be correlated with clinical, laboratory and other related findings.



5.2% [D] N

